

The Association Isoflurane-verapamil Causes Regional Left-ventricular Dyssynchrony in the Dog

Michel Videcoq, M.D.,* Charles C. Arvieux, M.D.,† James G. Ramsay, B.Sc., M.D.,‡ Pierre Foëx, M.D., D.Phil.§ J. Gilbert Stone, M.D.,¶ W. Alan Ryder,** Lee A. Jones††

In ten dogs anesthetized with 1% inspired isoflurane, the effect of low-dose verapamil on global and regional myocardial function was studied. The administration of verapamil resulted in no change in heart rate or blood pressure, but left ventricular stroke work, peak power, LV dP/dt max, and aortic blood acceleration were significantly reduced, while coronary blood flow remained unchanged. End-diastolic length increased in territory supplied by both left anterior descending (LAD) and left circumflex (LC) artery, but a significant decrease in systolic shortening occurred in the LAD segment only. Dyssynchrony of wall motion, characterized by post-systolic shortening, accompanied in three animals by a small amount of systolic lengthening, appeared with the administration of verapamil and was more pronounced in the LAD segment. Such patterns of wall motion have usually been attributed to myocardial ischemia. In the absence of significant reduction in coronary blood flow, and in the presence of a delay in onset of shortening and lengthening, these patterns of wall motion are more likely to reflect dyssynchrony of regional function than ischemia. (Key words: Anesthetics, inhalation: isoflurane. Calcium channel blockers: verapamil. Heart: regional ventricular function.)

THE INTERACTIONS OF calcium channel blockers, especially verapamil, with inhalation anesthetics have been studied extensively. Comparisons of the interactions between verapamil and halothane, enflurane, or isoflurane have shown that, at low plasma concentrations of verapamil (less than $100 \text{ ng} \cdot \text{ml}^{-1}$), verapamil-isoflurane causes less global cardiac depression than verapamil-enflurane or verapamil-halothane.¹ The negative inotropic effect of verapamil is already present at

plasma concentrations as low as $35 \text{ ng} \cdot \text{ml}^{-1}$, in open chest preparations,² but is relatively small even at much higher concentrations in closed chest preparations.^{3,4}

In this study, we evaluated the effect of a low dose of intravenous verapamil on global and regional left ventricular function, during steady-state isoflurane anesthesia, in order to determine whether dyssynchrony of contraction as described with the association halothane-verapamil⁵ was also present with isoflurane-verapamil.

Methods

Ten mongrel dogs weighing between 15 and 21 kg were premedicated with morphine sulfate ($1 \text{ mg} \cdot \text{kg}^{-1}$) intramuscularly. Anesthesia was induced with thiopentone $10 \text{ mg} \cdot \text{kg}^{-1}$, the trachea was intubated, and constant volume intermittent positive pressure ventilation was instituted with a nitrogen:oxygen (2:1) mixture, with carbon dioxide added to maintain normocarbica. During surgical preparation, anesthesia was maintained with halothane. Temperature, monitored at the mid esophagus, was maintained between 37 and 38°C by a heating element incorporated in the operating table.

An intravenous cannula was placed in the femoral vein for infusion of 0.9% saline at a constant rate of $4 \text{ ml} \cdot \text{kg}^{-1} \cdot \text{h}^{-1}$ by an infusion pump, and a rigid 14-gauge polyethylene catheter was inserted in the left common carotid artery and advanced to within 1 cm of the aortic valve for measurement of systemic arterial pressure (Statham pressure transducer).

A left thoracotomy was performed, the fifth and sixth ribs excised, and the heart exposed and suspended in a pericardial cradle. A cannula was inserted into the pulmonary artery *via* the outflow tract of the right ventricle for determination of cardiac output (dye dilution), and a rigid 14-gauge cannula was inserted into the left ventricle *via* a stab wound in the apical dimple for measurement of pressure (Statham pressure transducer).

The aortic root was dissected free of its fat pad, and an appropriately sized electromagnetic flow transducer (SEM 230, SE laboratories) was placed around it. In the first seven dogs, the left anterior descending coronary artery (LAD) was then dissected free distal to the second major diagonal branch, and an electromagnetic flow transducer (SEM 230, SE laboratories) was placed around it.

* Anesthetist, Department of Anesthesia and Intensive Care, Hôpital Bichat, University Paris VII, Paris, France.

† Associate Professor, Department of Anesthesia and Intensive Care, University of Grenoble, Grenoble, France.

‡ Assistant Anaesthetist, Royal Victoria Hospital, Assistant Professor of Anaesthesia, McGill University, Montreal, Canada.

§ Clinical Reader and Honorary Consultant (Clinical Physiology), Nuffield Department of Anaesthetics.

¶ Associate Professor of Anesthesia, College of Physicians and Surgeons, Columbia University, New York, New York.

** Chief Technician, Nuffield Department of Anaesthetics.

†† Laboratory Technician, Nuffield Department of Anaesthetics.

Received from the Nuffield Department of Anaesthetics, Oxford University, Oxford, England. Accepted for publication May 26, 1987. Supported in part by grants no. G8002204SA and G8306850SA from the Medical Research Council and by a Fellowship from Abbott Laboratories (France). Presented in part at the Anaesthetic Research Society Meeting, Leicester, March 1985. Dr. Ramsay was the recipient of a McLaughlin Travelling Fellowship (Canada).

Address reprint requests to Dr. Videcoq: Department D'Anesthésie Réanimation, Hôpital Bichat, 46 Rue Henri Huchard, 75018 Paris, France.

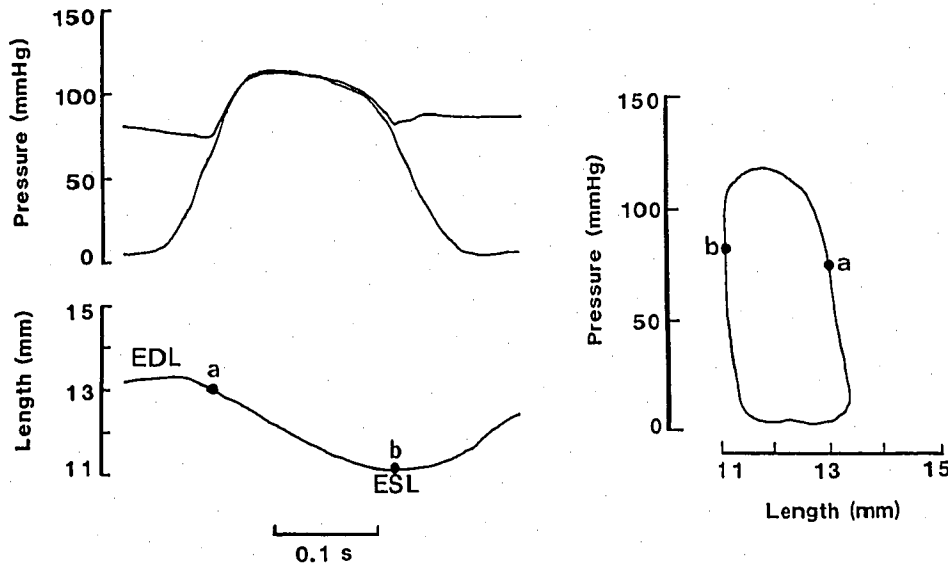


FIG. 1. The left panel shows fast recordings ($250 \text{ mm} \cdot \text{s}^{-1}$) of aortic and ventricular pressures and segment length. EDL denotes end diastolic and ESL end systolic length; (a) denotes the time of aortic valve opening and (b) the time of aortic valve closure. The right panel shows the same signals displayed as pressure-length loop.

Two pairs of ultrasonic piezo-electric crystals were inserted at the level of the subendocardium, parallel to the short axis of the heart. One pair was implanted in the apical area supplied by the left anterior descending coronary artery (LAD), and the other in the upper part of the free wall of the left ventricle supplied by the left circumflex coronary artery (LC).

Regional myocardial function was assessed by continuous measurement of segment length between each pair of crystals, based on the transit time of ultrasound.^{6,7} The transit time signal may be converted into a length signal as ultrasound travels through the myocardium at a constant velocity of $1.56 \text{ mm} \cdot \mu\text{s}^{-1}$.

Regional dimensions were measured as follows: end-diastolic length (EDL) was measured at the time of the beginning of the sharp upslope of the first derivative of the left ventricular pressure (LV dP/dt) signal; end-systolic length (ESL) was measured at the time of closure of the aortic valve, as indicated by the time when aortic flow tracing crosses the zero line; and maximum and minimum lengths during systole (L_{maxS} and L_{minS}), and minimum length during diastole (L_{minD}) were also measured. Percentage of systolic and post-systolic shortening (% SS, % PSS) were derived from these lengths as follows:

$$\% \text{ SS} = \{(L_{\text{max S}} - L_{\text{min S}}) / L_{\text{max S}}\} \times 100$$

$$\% \text{ PSS} = \{(ESL - L_{\text{min D}}) / (L_{\text{max S}} - L_{\text{min D}})\} \times 100$$

In a normal segment, $L_{\text{min S}}$ occurs at the end of systole, and $L_{\text{max S}}$ occurs at the end of diastole or just at the beginning of systole (due to atrial contraction). However, in abnormal segments, L_{min} may occur dur-

ing diastole. Similarly, an increase in length may develop after aortic valve opening, in which case there is systolic bulge. The simultaneous recordings of left ventricular pressure and regional dimensions makes it possible to examine their time course and to obtain pressure-length loops. A normal trace is shown in figure 1, together with aortic and left-ventricular pressures. The loop plotted besides the trace shows the dynamic relationship between length and pressure, and the stages of the cardiac cycle with reference to opening and closure of the aortic valve. Abnormal patterns of wall motion are displayed in figure 2, showing systolic bulge and post-systolic shortening.

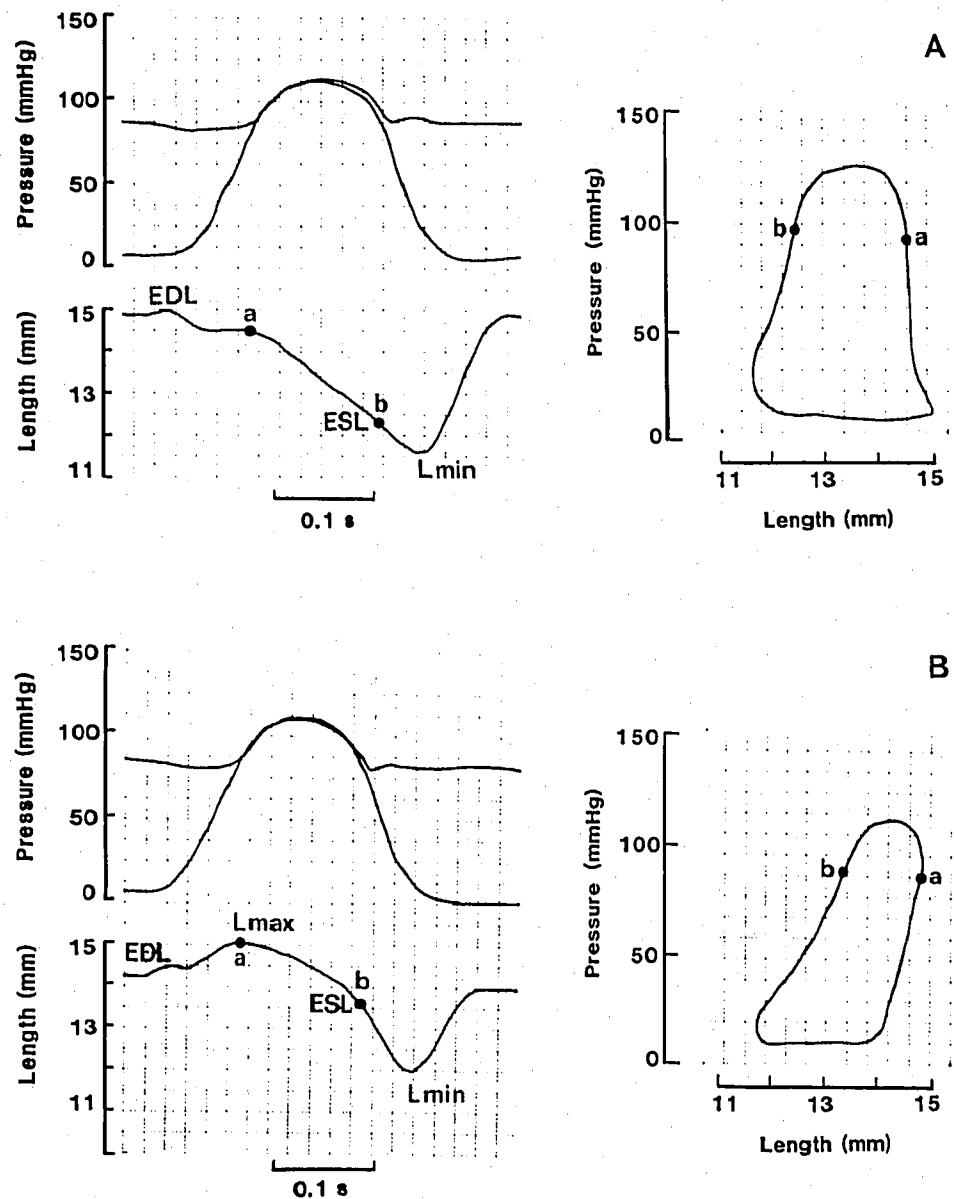
The onset of regional shortening and lengthening was measured with reference to the time when the LV dP/dt signal reached $200 \text{ mmHg} \cdot \text{s}^{-1}$.

ECG (lead II), PR interval, aortic and left ventricular pressures, aortic flow, and aortic blood acceleration (differentiation of the flow signal) were recorded simultaneously, together with the length signals. Stroke volume was obtained by on-line integration of the flow signal, and was calibrated by triplicate determination of cardiac output by dye dilution. Derived hemodynamic variables were calculated using conventional methods.

The signals were recorded on a mingograph 81 eight channel recorder (Elema Schonander, Stockholm, Sweden) at a paper speed of $250 \text{ mm} \cdot \text{s}^{-1}$.

As an index of early global diastolic function, the time constant of isovolumic relaxation (T_{relax}) was calculated.⁸ This is achieved by regression analysis of the logarithms of instantaneous values of pressure against time, for the period from aortic valve closure to the time when LV pressure reaches 10 mmHg above LVEDP.

FIG. 2. Two examples of dys-synchrony of contraction. A. The length trace (left) shows that Lmin is shorter than ESL and occurs after aortic valve closure (post-systolic shortening). Because of post-systolic shortening, the loop bulges to the left. Abbreviations as in figure 1. B. The length trace (left) shows that Lmax is greater than EDL (systolic lengthening) and Lmin is shorter than ESL (post-systolic shortening). These changes in regional contraction cause the pressure-length loop to "tilt" to the right and later to bulge to the left. Abbreviations as in figure 1.



Blood samples for measurement of plasma verapamil concentration by high-pressure liquid chromatography⁹ were obtained at the end of the loading dose, and 30 min after the start of the maintenance infusion.

Statistical analysis was performed using paired Student's *t* tests, the null hypothesis being rejected when *P* was less than 0.05.

Protocol

After completion of the surgical preparation, halothane was replaced by isoflurane (1% inspired), delivered by a Cyprane vaporizer calibrated by mass spectrometry. Blood gases were analyzed and, where neces-

sary, ventilation adjusted to ensure normocarbia, and sodium bicarbonate given to control metabolic acidosis. An hour was allowed to elapse after the introduction of isoflurane before control measurements were recorded. At the time halothane was replaced by isoflurane, surgery had been completed, and, for the duration of the study, the animals did not breathe or move, even though muscle relaxants were not administered.

Verapamil was then given intravenously as a loading dose of 250 $\mu\text{g} \cdot \text{kg}^{-1}$ over 30 min, followed by a maintenance dose of 60 $\mu\text{g} \cdot \text{kg}^{-1} \cdot \text{h}^{-1}$. The effects of verapamil were recorded 30 min after the start of the maintenance dose.

TABLE 1. Effect of Verapamil iv Infusion on LV Global Hemodynamics, Diastolic Relaxation, and LAD Coronary Perfusion in Ten Dogs (Mean \pm SEM)

	Control	Verapamil
HR (b \cdot min ⁻¹)	113 \pm 5	119.7 \pm 4.6
MAP (mmHg)	93.2 \pm 5.1	90 \pm 5.9
PR interval (ms)	99.2 \pm 3.8	128.2 \pm 1.1†
SV (ml \cdot kg ⁻¹)	1.19 \pm 0.09	0.95 \pm 0.08†
CO (ml \cdot min ⁻¹ \cdot kg ⁻¹)	131.5 \pm 9.4	112.7 \pm 9.2*
Aortic blood accel. (ml \cdot s ⁻²)	6389 \pm 514	4319 \pm 480‡
LV stroke work (mj)	14.6 \pm 1.1	11.43 \pm 1.2†
LV peak power (mW)	3424 \pm 280	2577 \pm 303†
LV dP/dt max (mmHg \cdot s ⁻¹)	1603 \pm 115	1280 \pm 119‡
SVR (dyne \cdot s ⁻¹ \cdot cm ⁻³)	2870 \pm 203	3288 \pm 278*
LVEDP (mmHg)	4.85 \pm 0.5	5.9 \pm 0.3*
Negative LV dP/dt (mmHg \cdot s ⁻¹)	1885 \pm 119	1645 \pm 137†
T relax (ms)	28.6 \pm 1.2	33.2 \pm 1.6†
LAD blood flow (ml \cdot min ⁻¹ \cdot 100 g ⁻¹)	81.2 \pm 6.3	73.2 \pm 8.1
Coronary perfusion pressure (mmHg)	75.9 \pm 4.4	69.5 \pm 5

LAD = left anterior descending coronary artery.

* $P < 0.05$.† $P < 0.01$.‡ $P < 0.0001$.

Results

PLASMA VERAPAMIL CONCENTRATIONS

The mean plasma concentration of verapamil, at the end of the loading dose, was 68.7 ng \cdot ml⁻¹ (SD \pm 20.6), 45.5 ng \cdot ml⁻¹ (SD \pm 10.6) 30 min, and 49.6 ng \cdot ml⁻¹ (SD \pm 11.2) 90 min after the start of the maintenance dose. Norverapamil was not detectable in these samples.

GLOBAL HEMODYNAMICS

Hemodynamic data are shown in table 1.

The administration of verapamil produced no significant changes in heart rate and arterial pressure, but a significant increase in PR interval was observed. Global cardiac performance was significantly depressed. There was a 20% decrease in stroke volume ($P < 0.005$), a 15%

decrease in cardiac output ($P < 0.015$), and significant decreases in aortic blood acceleration, LV stroke work, LV peak power, and LV dP/dt max. At the same time, systemic vascular resistance and LVEDP increased significantly. Relaxation was impaired, as evidenced by an increase in T relax and a decrease in peak negative LVdP/dt.

Coronary blood flow and coronary perfusion pressure remained unchanged.

REGIONAL FUNCTION

Regional function data are displayed in table 2.

A significant increase in end-diastolic length in both LAD and LC territories was observed with verapamil, suggesting ventricular dilatation.

A 36% decrease in the percentage of systolic shortening ($P < 0.0001$) occurred in the LAD segment, but not in the LC segment. Post-systolic shortening appeared in both segments with the administration of verapamil. In addition, systolic lengthening (bulge) was observed in three dogs, being more marked in the LAD territory.

There was a significant effect of verapamil on the time course of regional contraction. The onset of systolic shortening was significantly delayed in the LAD segment, and the onset of diastolic lengthening delayed in both segments.

Discussion

The plasma concentrations of verapamil obtained in these experiments were slightly higher than those reported by Kates *et al.*² (about 45 ng \cdot ml⁻¹ compared to 35 ng \cdot ml⁻¹), but correspond to the lowest levels in the study by Kapur *et al.*¹ and Campos and Kapur.¹⁰

During steady-state isoflurane anesthesia, verapamil increased atrio-ventricular conduction time and caused significant reductions of all indices of global left ventricular performance, accompanied by a small but significant increase in LVEDP. The negative dromotropic and inotropic effects of verapamil were accompanied by

TABLE 2. Effect of Verapamil iv Infusion on Regional Hemodynamics in Ten Dogs (Mean \pm SEM)

	Apical Region		Basal Region	
	Control	Verapamil	Control	Verapamil
EDL (mm)	13.1 \pm 0.6	13.6 \pm 0.6†	13.2 \pm 0.8	13.6 \pm 0.8†
% SS (%)	17 \pm 1.7	10.9 \pm 2‡	13.8 \pm 0.9	12.3 \pm 2.7
% PSS (%)	0	25.3 \pm 8.3†	5.7 \pm 2.6	16.1 \pm 4.8†
syst. bulge (mm)	0	0.07 \pm 0.03*	0.03 \pm 0.03	0.07 \pm 0.06
short. delay (ms)	66.6 \pm 3.2	86 \pm 6.3†	64.6 \pm 3.6	69.4 \pm 3.5
length. delay (ms)	250 \pm 20	300 \pm 10†	280 \pm 10	300 \pm 10†

EDL = end-diastolic length; SS = systolic shortening; PSS = post-systolic shortening.

* $P < 0.05$.† $P < 0.01$.‡ $P < 0.001$.

an increase in systemic vascular resistance and a reduction of cardiac output. These findings are in agreement with those of Kates *et al.*² who used a canine cardiopulmonary bypass preparation but differ from those of Kapur *et al.*¹ who used an intact animal preparation. Similarly, our observations differ from those of Chelly *et al.*³ and Rogers *et al.*,⁴ who showed moderate depression of cardiac performance when infusions of verapamil were administered during halothane, enflurane, or isoflurane anesthesia, even though verapamil plasma levels were higher than in this study. In an open-chest preparation, the effects of positive inotropic interventions can be expected to be blunted and those of negative inotropic interventions to be exaggerated.¹¹ This may explain why our observations and those of Kapur *et al.*¹ differ. However, acute, invasive preparations may be more like the clinical surgical situation, particularly thoracic surgery, than is the non-invasive, non-stimulated preparation without any surgery. With the low dose of verapamil used in this study, atrio-ventricular dissociation would not be expected to develop and, indeed, only an increase in PR interval was observed.

Kates *et al.*² did examine regional function, but reported their findings solely in terms of regional systolic shortening. They used ultrasonic length detectors placed in the mid-wall of the left ventricle, and found that the addition of low-dose verapamil to isoflurane (1.05% end-tidal) reduced systolic shortening from 16% to about 12%. This is similar to the effect we have observed in the apical region, where shortening was reduced from 17% to 11% by the addition of verapamil. In the upper part of the left ventricular wall, shortening was not significantly modified. In their extensive investigations of the interactions between calcium blocking drugs and inhalational anesthetics, Chelly *et al.*³ and Rogers *et al.*⁴ examined regional ventricular function in terms of maximal length change from end-diastolic length. Reductions in absolute shortening caused by verapamil were found to be relatively small, and often did not reach statistical significance.

Previous work in this laboratory has shown that cumulative bolus administration of verapamil during halothane anesthesia caused regional dysfunction in the left ventricle.⁵ In the present study, the continuous infusion of verapamil during isoflurane anesthesia caused significant post-systolic shortening in the apical region of the left ventricle. This is particularly obvious when pressure-length loops are examined (fig. 3). In the basal region of the left ventricle, the small amount of PSS (6%) that was present in the control state was significantly increased (to 16%) by verapamil. It must be noted that, in this region, a small amount of PSS (about 5–6%) is frequently present.^{12,13}

Post-systolic shortening is usually attributed to myo-

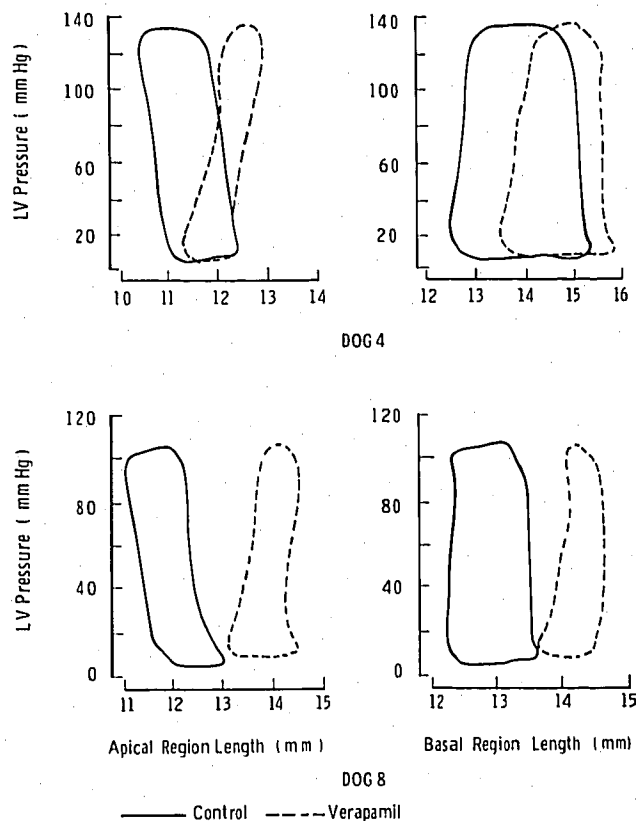


FIG. 3. Contrasting with the normal pressure-length loops before verapamil (full line loops), the pressure-length loops after verapamil (dotted line loops) show rightward shift indicative of segmental dilatation and "tilt" to the right associated with systolic lengthening and post-systolic shortening. These changes are more pronounced in the LAD than in the LC supply territory. The upper loops are from dog 4, where LAD artery was dissected, while the lower loops are from dog 8, where the LAD artery was undisturbed.

cardial ischemia,^{7,13,14,15} and has been observed when nitrous oxide was added to fentanyl and sufentanil in the presence of critical coronary artery stenosis.¹¹ In the present study, PSS occurred at a time when coronary perfusion pressure was well maintained, and the 10% reduction of coronary blood flow which occurred with verapamil was not statistically significant. A similar insignificant effect of low dose verapamil during isoflurane anesthesia has been reported by Campos and Kapur.¹⁰

Thus, PSS was unlikely to have been caused by myocardial ischemia. Because total LAD coronary blood flow, and not its regional distribution, was measured, undetected redistribution away from the subendocardium could have taken place. However, diastolic wall tension is unlikely to have increased enough to have caused significant redistribution of subendocardial blood flow, and, hence, ischemia, as there was only a small increase in LVEDP (1 mmHg) associated with

small increases in end-diastolic segment length. It must be stressed that, in previous studies,^{7,13} larger increases in LVEDP and end-diastolic length in response to deepening halothane anesthesia were observed, and did not cause post-systolic shortening unless critical coronary artery constriction was present.

Another possible cause of PSS is ischemic damage induced by coronary artery dissection. If this was the case, PSS should have been observed in the LAD territory in the control stage (isoflurane alone) which was recorded 1 h after the end of surgery and implantation of the ultrasonic length detectors. This was not the case. In our experience with this model, PSS does not occur spontaneously as a consequence of deterioration of the preparation with the passage of time, and careful coronary artery dissection does not cause regional dysfunction.¹¹ Indeed, in three animals in which the LAD artery was not dissected, regional dysfunction was also observed after verapamil. It must also be stressed that higher concentrations of isoflurane alone, do not cause regional dysfunction.‡‡

We would, therefore, argue that PSS in the apex of the left ventricle was not caused by ischemia or by coronary artery damage, but was due to an interaction between verapamil and isoflurane resulting in a delay in the onset of contraction and relaxation. Indeed, in the apical region, activation (the start of shortening) was delayed by about 20 ms, and relaxation (the start of lengthening) by about 50 ms. In contrast, in the upper part of the left ventricle, activation was delayed by only 5 ms and relaxation by 20 ms. The greater delay in activation (20 ms *vs.* 5 ms) and relaxation (50 ms *vs.* 20 ms) observed in the apical region could explain the small amount of systolic lengthening and the substantial amount of PSS in the apical region. The regional delay in relaxation may be partly responsible for the observed impairment of global relaxation, demonstrated by reduced peak negative dP/dt, and prolonged T relax.

Although halothane had been discontinued for at least 1 h before the start of study of the interaction between isoflurane and verapamil, some residual effect of halothane cannot be excluded. Indeed, Spiss *et al.*¹⁶ have shown that, for 2 h after discontinuation of halothane, vascular responsiveness remains depressed. However, any effect of halothane would be expected to have been greater at the time that control measurements were taken, and smaller when the interaction verapamil-isoflurane was recorded. This would have led to underestimation, rather than overestimation, of this interaction.

Serruys *et al.* interpreted the changes in wall motion that they observed in man after intracoronary nifedipine as delayed activation and relaxation.¹⁷ If the regional dysfunction we observed was due to a delay in activation, either a delay in the arrival of the electrical impulse or delay in the coupling between excitation and contraction may have been responsible. We favour the latter, as neither isoflurane nor verapamil affect ventricular conduction.^{18,19} Both calcium channel antagonists and inhalational anesthetics interfere with the movement of calcium ions either into or within the myocyte;²⁰⁻²³ these ion movements are intimately involved with all phases of contraction. From a theoretical standpoint, then, it is not surprising that this drug combination should have a potent effect on the process of excitation-contraction-relaxation. Recent work by Lynch²⁴ suggests that decreased Ca²⁺ entry contributes little to the negative inotropy of isoflurane, while an alteration in myocardial sarcoplasmic reticulum uptake/release may play an important role. Further electrophysiological studies at the cellular level, in the presence of verapamil and isoflurane, are needed to test this hypothesis. That dysfunction has not been reported by other groups previously is not surprising. Unless pressure-length loops or fast recordings, including aortic blood flow, are obtained, the exact timing of end-ejection cannot be determined with certainty, and total shortening may easily be reported as systolic shortening, even though a substantial proportion of shortening occurred after the end of ejection.

Dyssynchrony of ventricular contraction impairs its overall performance. If shortening occurs when relaxation should be taking place, coronary blood flow may be decreased, compromising oxygen supply to the affected (dysynchronous) region. If coronary blood flow is already compromised, adding verapamil to isoflurane could result in a worsening of regional ischemia.

In summary, the addition of verapamil to isoflurane results in a reduction in global performance of the LV, and impairment of regional contraction, especially in the territory of the LAD.

The disturbance of contraction is characterized by a delay in regional shortening and relaxation which will result in dyssynchrony, characterized by paradoxical systolic lengthening (bulge) and post-systolic shortening, both of which reduce the efficiency of global contraction. Underlying dysfunction may be expected to be worsened with this drug combination, with the additional possibility of worsening of preexisting oxygen supply/demand imbalance.

References

1. Kapur PA, Bloor BC, Flake WE, Olewine SK: Comparison of cardiovascular responses to verapamil during enflurane, isoflu-

‡‡ Cutfield GR: The Effect of Anaesthesia and its Interaction with critically reduced Coronary Perfusion upon Myocardial Function. D.Phil. Thesis, University of Oxford, Oxford, U. K.

- rane or halothane anesthesia in the dog. ANESTHESIOLOGY 61:156-160, 1984
2. Kates RA, Kaplan JA, Guyton RA, Dorsey L, Hug CC, Hatcher CR: Hemodynamic interactions of verapamil and isoflurane. ANESTHESIOLOGY 59:132-138, 1983
 3. Chelly JE, Rogers K, Hysing ES, Taylor A, Hartley C, Merin G: Cardiovascular effects of and interactions between calcium blocking drugs and anesthetics in chronically instrumented dogs. I. Verapamil and halothane. ANESTHESIOLOGY 64:560-567, 1986
 4. Rogers K, Hysing ES, Merin G, Taylor A, Hartley C, Chelly JE: Cardiovascular effects of and interactions between calcium blocking drugs and anesthetics in chronically instrumented dogs. II. Verapamil, enflurane and isoflurane. ANESTHESIOLOGY 64:568-574, 1986
 5. Ramsay JC, Cutfield GR, Francis CM, Devlin WH, Foëx P: Halothane-verapamil causes regional myocardial dysfunction in the dog. Br J Anaesth 58:321-326, 1986
 6. Bugge-Asperheim B, Leraand S, Kiil F: Local dimensional changes of the myocardium measured by ultrasonic technique. Scand J Clin Lab Invest 24:361-371, 1969
 7. Lowenstein E, Foëx P, Francis CM, Davies WL, Yusuf S, Ryder WA: Regional ischemic dysfunction in myocardium supplied by a narrowed coronary artery with increasing halothane concentration in the dog. ANESTHESIOLOGY 55:349-359, 1981
 8. Frederiksen JW, Weiss JL, Wiesfeldt ML: Time constant of isovolumic pressure fall: Determination in the working left ventricle. Am J Physiol 235:H701-706, 1978
 9. Cole SC, Flanagan RJ, Johnston A, Holt DW: Rapid high-performance liquid chromatographic method for the measurement of verapamil and norverapamil in blood plasma and serum. J Chromatogr 218:621-629, 1981
 10. Campos JH, Kapur PA: Combined effect of verapamil and isoflurane on coronary blood flow and myocardial metabolism in the dog. ANESTHESIOLOGY 64:778-784, 1986
 11. Vatner SF, Braunwald E: Cardiovascular control mechanisms in the conscious state. A comparison of the effects of physiological and pharmacological stimuli in the presence or absence of general anesthesia. N Engl J Med 293:970-976, 1975
 12. Philbin DM, Foëx P, Drummond G, Lowenstein E, Ryder WA, Jones LA: Post-systolic shortening of canine left ventricle supplied by a stenotic coronary artery when nitrous oxide is added in the presence of narcotics. ANESTHESIOLOGY 62:166-174, 1985
 13. Francis CM, Foëx P, Lowenstein E, Glazebrook CW, Davies WL, Ryder WA, Jones LA: Interaction between regional myocardial ischaemia and left ventricular performance under halothane anaesthesia. Br J Anaesth 54:965-980, 1982
 14. Forrester JS, Wyatt HL, Duluz PL, Tyberg JV, Diamond G, Swann HJC: Functional significance of regional ischemic contraction abnormalities. Circulation 54:64-70, 1976
 15. Waters DD, Da Luz PL, Wyatt HL, Swann HJC, Forrester JS: Early changes in regional and global left ventricular function induced by graded reduction in regional coronary perfusion. Am J Cardiol 39:537-543, 1977
 16. Spiss CK, Smith CM, Tsujimoto G, Hoffman BB, Maze M: Prolonged hyporesponsiveness of vascular smooth muscle contraction after halothane anesthesia in rabbits. Anesth Analg 64:1-6, 1985
 17. Serruys BN, Hooghoudt TEH, Reiber JHC, Slager C, Brower RW, Hugenholtz PG: Influence of intracoronary nifedipine on left ventricular function, coronary vasomotility, and myocardial oxygen consumption. Br Heart J 49:427-441, 1983
 18. Blitt CD, Raessler KL, Whightman MA, Groves BM, Wall CL, Geha DG: Atrioventricular conduction in dogs during anesthesia with isoflurane. ANESTHESIOLOGY 50:210-212, 1979
 19. Mangiardi LM, Hariman RJ, McAllister RG Jr, Bhargava V, Surawicz B, Shabetai R: Electrophysiologic and hemodynamic effects of verapamil, correlation with plasma drug concentrations. Circulation 57:366-372, 1978
 20. Reuter H: Ion channel in cardiac cell membranes. Annu Rev Physiol 45:473-484, 1984
 21. Lynch C, Vogel S, Sperelakis N: Halothane depression of myocardial slow action potentials. ANESTHESIOLOGY 55:360-368, 1981
 22. Blanck JJ, Thompson M: Calcium transport by cardiac sarcoplasmic reticulum: Modulation of halothane action by substrate concentration and pH. Anesth Analg 60:390-394, 1981
 23. Blanck JJ, Thompson M: Enflurane and isoflurane stimulate calcium transport by cardiac sarcoplasmic reticulum. Anesth Analg 61:142-145, 1982
 24. Lynch C: Differential depression of myocardial contractility by halothane and isoflurane *in vitro*. ANESTHESIOLOGY 64:620-631, 1986