

Contrast Echocardiography: A Method to Visualize Changes in Regional Myocardial Perfusion in the Dog Model for CABG Surgery

S. Aronson, M.D.,* E. Bender, M.D.,† S. B. Feinstein, M.D.,‡ P. H. Heidenreich, B.S.,§
J. Ellis, M.D.,* C. Dick, M.D.,¶ M. F. Roizen, M.D.,** R. B. Karp, M.D.††

The ability of contrast echocardiography to assess regional myocardial perfusion during cardiopulmonary bypass in a dog model for coronary artery bypass surgery was evaluated. Sonicated Renograffin-76 microbubbles (meglumin diatrizoate and sodium diatrizoate) were injected into an aortic root proximal to an aortic occlusion clamp root while dogs were on cardiopulmonary bypass, with the heart arrested in diastole. Echocardiographic contrast-enhanced regions of myocardial perfusion were easily visualized. Differences in contrast-enhanced myocardial regions depended on coronary artery occlusion or patency. The contrast-enhanced images of myocardial perfusion showed that, for a given myocardial segment of the supplying vessel, the presence or absence of contrast effect reliably predicted vessel occlusion or patency ($P < .01$). In the future contrast echocardiography may allow the direct assessment of regional myocardial perfusion in the operating room. (Key words: Measurement techniques: contrast echocardiography; microbubble; Renograffin. Monitoring: transesophageal echocardiography. Surgery, cardiac: coronary artery bypass graft.)

MANY CLINICAL and research questions could be answered if a method were available to quantify regional myocardial perfusion. For example, if the cause of myo-

cardial ischemia in a patient during cardiovascular surgery were identified, a logical treatment could be instituted. The method could then be used to assess the effectiveness of that therapy. Similarly, results of new bypass grafts on perfusion of myocardial tissue could be assessed to decide if additional bypass grafts were needed. To date, conventional imaging techniques only indirectly indicate the adequacy of regional myocardial perfusion.¹ Coronary arteriography quantitates the lumen size of major coronary arteries but does not evaluate how well blood from that lumen perfuses myocardial tissue.² Electrocardiographic, echocardiographic, and radionuclide studies enable analysis of the indirect metabolic or functional consequences of perfusion, but these techniques do not provide a method to directly assess myocardial perfusion.

Contrast echocardiography is a technique that has been used in a variety of clinical settings to detect intracardiac shunts³ and valvular regurgitation,⁴ to assess cardiac chambers,⁵ to enhance endocardial border detection, to measure cardiac output,⁶ and to evaluate mitral valve surgical results intraoperatively.⁷ Recently, contrast echocardiography has been used noninvasively to define myocardial perfusion.^{8,9}

Previous investigators have shown that contrast echocardiography can successfully determine the extent of regional myocardial blood flow that results from coronary artery stenosis and occlusion in experimental animals and humans.¹⁰⁻¹³ Thus far, the success of contrast echocardiography in delineating changes in regional myocardial blood flow during cardiac surgery has been limited.

This report describes a new approach to the use of contrast echocardiography in dogs during cardiopulmonary bypass with the heart arrested during diastole. This approach may be used to evaluate regional myocardial perfusion in patients following coronary artery bypass surgery, while they are still on cardiopulmonary bypass, and prior to release of the aortic occlusive clamp.

Methods

Thirty-five contrast-enhanced myocardial perfusion patterns in six adult unpremedicated male mongrel dogs

This article is accompanied by an Editorial. Please see: Smith PK, Stanley TE III: Intraoperative contrast echocardiography: A direct approach to measure regional myocardial perfusion. ANESTHESIOLOGY 72:219-221, 1990.

* Assistant Professor of Anesthesia and Critical Care, University of Chicago.

† Instructor of Cardiac Surgery, University of Chicago.

‡ Assistant Professor of Internal Medicine, Division of Cardiology, University of Chicago.

§ Medical Student, University of Chicago.

¶ Fellow, Department of Cardiology, University of Minnesota.

** Professor and Chairman, Department of Anesthesia and Critical Care, University of Chicago.

†† Professor of Surgery, Chief Division of Cardiac Surgery, University of Chicago.

Received from the Department of Anesthesia and Critical Care, Cardiology and Cardiac Surgery, University of Chicago, Chicago, Illinois. Accepted for publication September 18, 1989.

Address reprint requests to Dr. Aronson: Assistant Professor, Department of Anesthesia and Critical Care, University of Chicago, 5841 S. Maryland Avenue, Chicago, Illinois 60637.

(15–25 kg) were studied after institutional approval was obtained. Our studies conformed to guidelines for animal care established by the American Physiological Society and the NIH.

General anesthesia was induced with pentobarbital (15–25 mg/kg iv) and oxygen. The trachea was intubated after muscle relaxation with pancuronium (0.2 mg/kg iv) and mechanical ventilation was provided using a Harvard animal ventilator. Further anesthesia was provided with additional pentobarbital (5 mg/kg iv) when signs of inadequate anesthesia (*e.g.*, increased heart rate or blood pressure of 20% or more) appeared. The right femoral artery and vein were cannulated to transduce systemic blood pressures and to administer iv fluids, respectively. The electrocardiogram was continuously displayed. After a midline sternotomy was performed and a pericardial cradle created, the dogs were given heparin (3 mg/kg iv) as an anticoagulant. A venous cannula was inserted into the right atrium and an arterial cannula was inserted into the ascending aorta. Cardiopulmonary bypass (CPB) was instituted at a flow of 50 ml/kg at 37° C.

The ascending aorta was occluded with a clamp and cardioplegia solution was infused into the proximal aortic root through one limb of a Y-type cardioplegia catheter until asystole occurred. The left anterior descending and the left circumflex coronary arteries were then identified and isolated with occlusion snares to selectively control perfusion to the region of myocardium subtended by each vessel.

Sterile Renograffin-76, commercially purchased, and a sonicator (Hect Systems-Ultrasonics, Inc.) were used to create air-filled bubbles of Renograffin with a method previously described.¹⁴ All injections were made for a

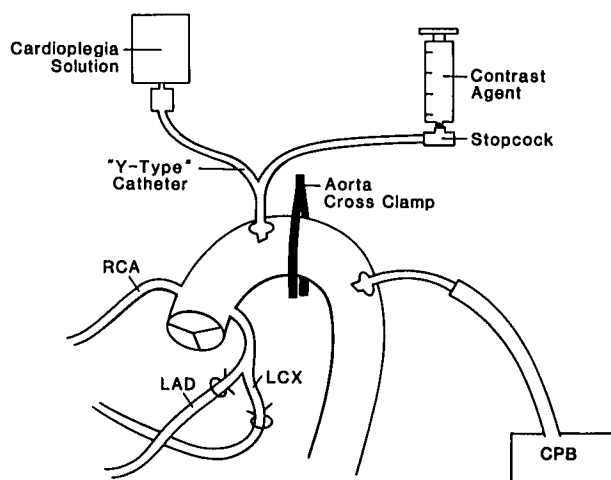


FIG. 1. The ascending aorta was occluded with a clamp and cardioplegia solution was infused into the proximal aortic root through one limb of a Y-type catheter while contrast was infused through the second limb of the Y-type catheter.

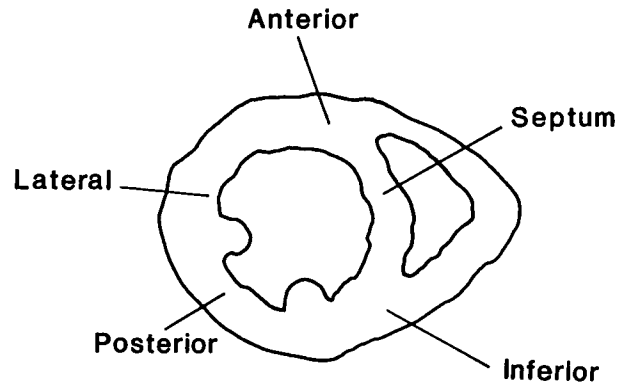


FIG. 2. Two-dimensional echocardiographic images were obtained of the short axis of the left ventricle at the midpapillary level by means of a hand-held scanner.

standardized time and volume using an automated injector system (Medrad, Mark IV, Pittsburgh, PA) through the second limb of the Y-type aortic root (cardioplegia) catheter during continuous infusion of cardioplegia solution (fig. 1).

Prior to injection of sonicated Renograffin, two-dimensional echocardiographic images were obtained of the short axis of the left ventricle at the midpapillary muscle level by means of a hand-held scanner. Optimal gain settings for visualization were obtained prior to injection and maintained throughout the study. Beginning about 15 s prior to each injection, the echocardiograph was monitored and recorded on videotape for approximately 2 min. During cardiopulmonary bypass and (approximately 10 min) after the proximal aorta was occluded, 4 ml of sonicated Renograffin was rapidly (2 s) injected into the aortic root in each of the following instances: 1) prior to any native coronary occlusion; 2) more than 2 and less than 4 min following random occlusion of either the LAD or LCX coronary artery; 3) 10 min following the release of the occlusion snare and presumed reinstatement of baseline coronary flow; 4) more than 2 and less than 4 min following occlusion of the other vessel (LAD or LCX); and 5) 10 min following release of the occlusion snare and presumed reinstatement of baseline coronary flow. Ultrasound reflectance was then analyzed off-line independently by three separate investigators who were blinded as to the order of the injection of contrast. For each injection, the presence or absence of contrast enhancement for regional myocardial perfusion was determined by each observer for anterior, lateral, septal, and posterior regions of the myocardium (fig. 2).

Statistical significance was determined using a chi-square analysis with $P < 0.01$ for statistical significance. Sensitivity and specificity were calculated for contrast effect. Sensitivity was defined as the number of times no contrast enhancement was observed in a region by any

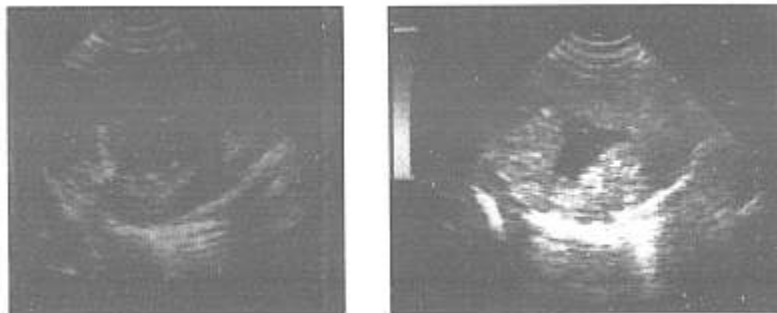
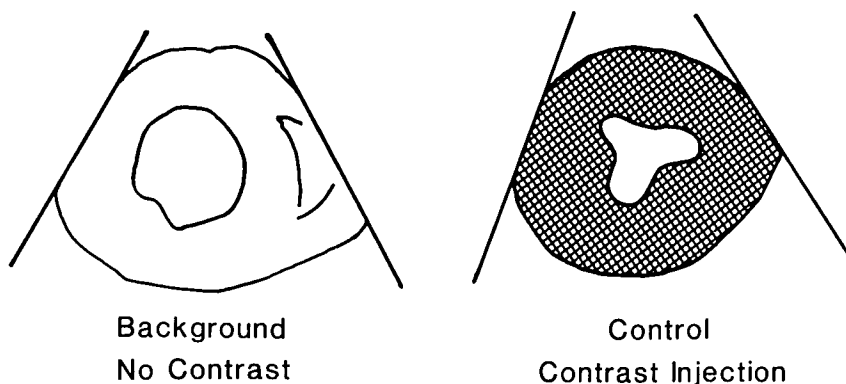


FIG. 3. Left ventricular echocardiographs obtained before (background) and immediately after (control) contrast injection without any native coronary arteries occluded.



observer divided by the number of times a vessel theoretically subserving that region was occluded. Specificity was defined as the number of times contrast enhancement was detected by all three observers divided by the number of times an injection was made into a nonoccluded vessel that theoretically subserved that region. Ultrasound reflectance was quantitated for regional myocardial segments in two dogs by means of a digitizing ultrasound system and off-line computer analysis. A modified commercial ultrasound scanner (ATL NK 600[®]) and a microcomputer, connected by a high-speed interface, were used to quantitate this reflectance.^{‡‡} Off-line analysis of data involved displaying the digitally reconstructed two-dimensional images on a terminal screen (512 by 512 pixels per frame with 64 levels of gray per pixel). Regions of interest were then outlined. Twenty-five consecutive images were analyzed using the same region of interest for each injection. These results were reported as mean pixel intensity (MPI) over the range of 0–255 grey level units, for 25 consecutive frames, and then averaged (μ is a unit of pixel intensity). Different injection patterns were compared using the averaged MPI for each of four myo-

cardial regions (anterior, septal, posterior, and lateral) by paired *t* tests and $P < 0.05$ as statistically significant.

Results

Echocardiographic visualization of the contrast effect was easily obtained in all dogs (figs. 3–5). All images were viewed by the participants of the study on-line as the contrast-enhanced perfusion patterns were recognized by observing the ultrasound monitor. All three observers visualized exactly the same contrast patterns independently off-line and thus only one reading is used per statistical analysis for all three observations (table 1).

Differences in contrast effects occurred depending on the vessel occluded (tables 1 and 2) and were significantly different from contrast effect when no vessel was occluded (tables 1 and 2, $P \leq 0.01$). There were no measurable changes in systemic hemodynamics during injection of contrast while dogs were on cardiopulmonary bypass. The presence or absence of contrast effect reliably predicted vessel occlusion or patency (table 3).

The digital data indicate that for a given myocardial segment of the supplying vessel, mean pixel intensity increased significantly less during vessel occlusion than it did during vessel patency (20μ vs. 80μ ; $P < .01$). In addition, no contrast effect was noted in the anterior septal regions when the LAD was occluded and minimal effect

^{‡‡} Ponsner S, Wood J, Prieto P, Charleston D, Feinstein S: High speed interface for myocardial sonicated echo contrast studies. Society of Photo-Optical Instrumentation Engineers 848:384–385, 1987.

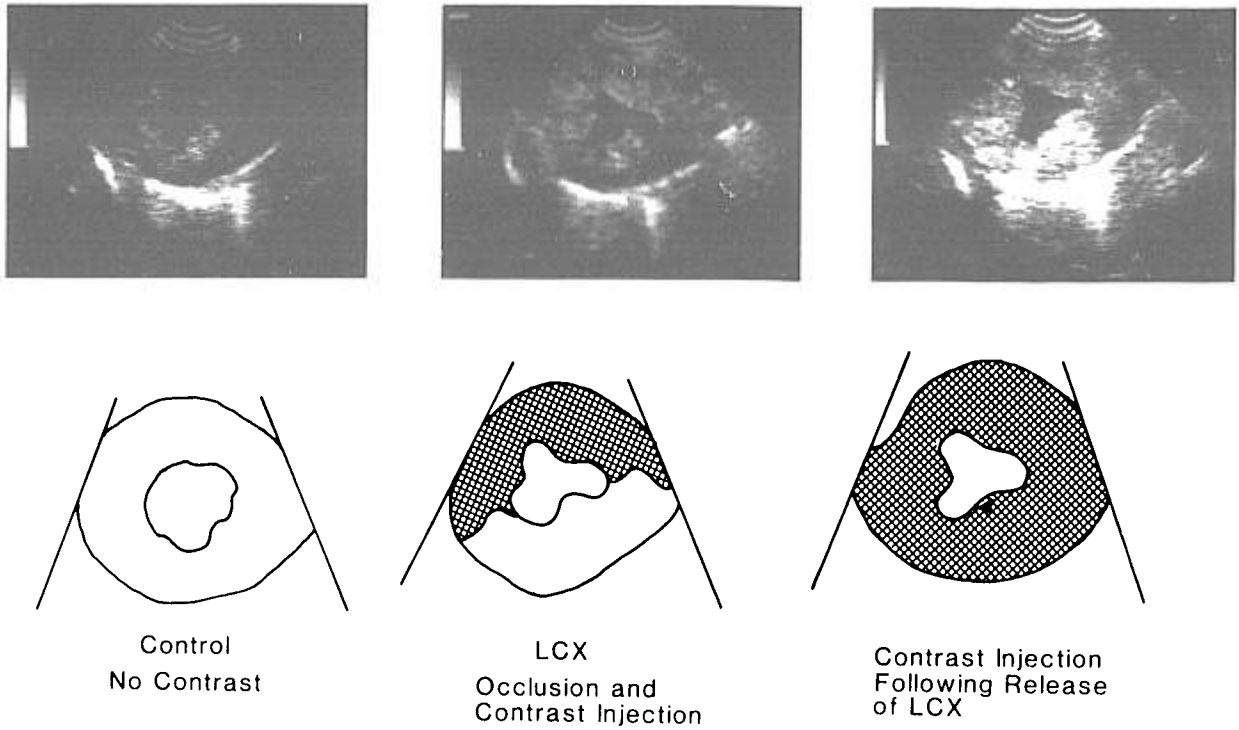


FIG. 4. Left ventricular echocardiographs obtained before contrast injection (left) and during contrast injections while the LCX coronary artery was occluded (center) and after the left circumflex (LCX) coronary artery was patent (right). To the left is the left ventricle free wall, to the right is the septum and at the top is the anterior wall of the left ventricle.

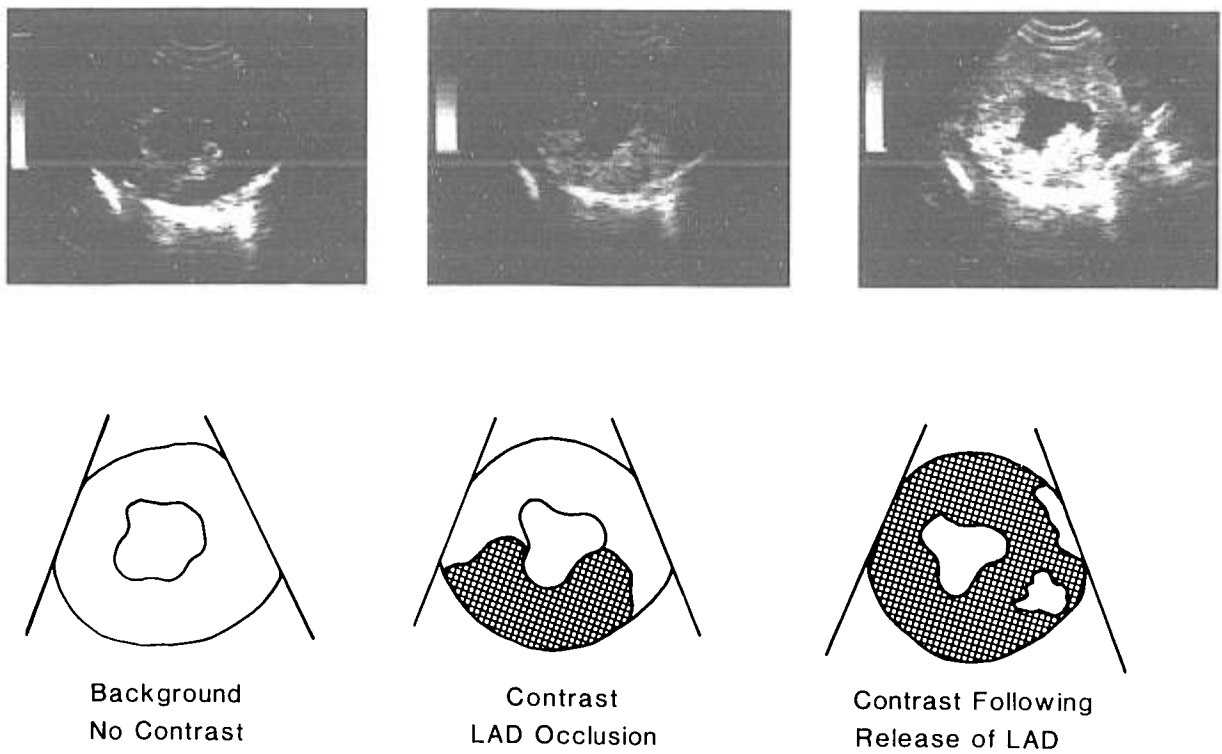


FIG. 5. Left ventricular echocardiographs representing the video images before contrast injection (left) during contrast injection with the left anterior descending coronary artery (LAD) occluded (center) and during contrast injection immediately following release of the LAD occlusive snare (right).

TABLE 1. Presence of Contrast in Specific Myocardial Regions as Determined by Observation

Total Number of Injections	Vessel Occluded	Times Contrast was Observed (by Region)			
		Septal*	Anterior*	Posterior*	Lateral
7	LAD	2†‡	0‡	7	6
7	LCX	5	4	0‡	0‡
21	No occlusions	21	21	21	21

* See figure 1 for our definition of regions on echograms.

† Thus, the septal region was visualized during 2 of the 7 total injections when the LAD was occluded.

‡ $P < 0.01$ compared to visualization of injections when no vessel was occluded.

TABLE 2. Mean Pixel Intensity in Each Myocardial Region as Analyzed by Computer with and without Contrast Injection

	Myocardial Region	Before Contrast Injection	After Contrast Injection		
		No Occlusion	No Occlusion	Occlusion	Occlusion
Dog 1	Septum	Background	Control	LCX	LAD
	Ant	23 (1.0)	73 (3.1)	82 (3.6)	35 (1.5)
	Lat	31 (1.0)	97 (3.1)	99 (3.2)	50 (1.6)*
	Post	39 (1.0)	114 (2.9)	43 (1.1)*	138 (3.5)*
		20 (1.0)	94 (4.7)	31 (1.55)*	108 (5.4)
Dog 2	Septum	37 (1.0)	93 (2.5)	67 (2.1)*	100 (2.5)
	Ant	32 (1.0)	86 (2.7)	76 (2.6)	47 (1.4)*
	Lat	29 (1.0)	73 (2.5)	36 (1.7)*	66 (1.7)
	Post	31 (1.0)	88 (2.8)	12 (1.2)*	79 (2.4)

Numbers are mean pixel intensity in $\mu \pm$ SD. (See text for method of calculation.)

* $P < 0.05$ by paired t tests when occlusion was compared with patency after contrast injection.

was noted in the posterior and lateral regions when the LCX was occluded (table 2). All intensity values were above baseline (no contrast injected) indicating moderate collateral flow in the canine myocardium.

The digital data, which used mean pixel intensity of ultrasound images, provided further validation of what the observers qualitatively reported after off-line analysis of the video ultrasound images.

Discussion

Location and size of an underperfused (ischemic) region of the heart are critical factors in assessing the prognosis and need for interventions in patients who sustain perioperative myocardial infarction or ischemia.¹⁵ This assessment is currently made in the operating room with electrocardiography and occasionally with two-dimensional echocardiography. While two-dimensional echocardiography allows determination of the anatomic and functional consequences of an infarcted or ischemic myocardium, it tends to overestimate and correlate poorly with infarct size in acute infarction models.¹⁶⁻¹⁹ Transesophageal echocardiography (TEE) is commonly used during surgery and anesthesia to assess myocardial function, volume status, and segmental wall motion changes.

The use of TEE has proven safe and reliable as a continuous technique for providing anatomically accurate images without hindering the operative procedure in any way. Because of the anatomic differences in the canine mediastinum that preclude adequate imaging with TEE, we used a hand-held transducer to obtain the characteristic short-axis view of the left ventricle at the level of the midpapillary muscle to simulate TEE clinical conditions. Because of the possible recruitment of collateral myocardial blood flow following temporary coronary artery occlusion,^{§§} we waited 10 min before reinjecting contrast after release of the respective coronary artery occlusive snare.

Various solutions and techniques have been used to introduce a contrast effect. We used sonicated Renografin-76 microbubbles (meglumin diatrizoate and sodium diatrizoate). Before the development of sonicated microbubble ultrasound agents, contrast echocardiography employed hand-agitated microbubbles that were relatively too large and variable in size and thus were unable to

§§ Armstrong W, Gage S: Evaluation of reperfusion hyperemia with myocardial contrast echocardiography. *Journal of the American Society of Echocardiography* 1:322-332, 1988.

TABLE 3. Sensitivity and Specificity of Contrast Detection

Absence of Perfusion	Occluded Vessel			
	LAD		LCX	
	Sensitivity*	Specificity†	Sensitivity	Specificity
Anterior	100%	89%	100%	100%
Septal	71%	93%	100%	96%
Posterior				
Lateral				

* Sensitivity was defined as the number of times no contrast enhancement was observed in a region by any observer divided by the number of times a vessel theoretically subserving that region was occluded.

† Specificity was defined as the number of times contrast enhancement was detected by all three observers divided by the number of times an injection was made into a nonoccluded vessel that theoretically subserved that region.

pass through the capillary bed without obstruction. Although hand-agitated microbubbles from both right- and left-sided injections in human studies have permitted evaluation of valvular regurgitation, cavity dimension, and intracardiac shunts without complications, these microbubbles did not allow tracking of echo reflective tracers through the microvasculature within the myocardium. The process of sonication, a method developed by Feinstein *et al.*,¹⁴ uses a high-frequency ultrasonic sonicator to produce a mixture of microcavitations that results in a smaller, more uniform bubble size than hand agitation produces. Sonication of contrast agent solutions is a practical and reliable technique that produces microbubbles small enough to readily traverse the capillary bed for distribution within the myocardial tissue. Microbubbles produced by the sonication of Renograffin-76 have been shown to be a reliable and safe contrast agent in experimental animals and human patients.^{20,21} A more stable microbubble, albumex®, currently under clinical investigation,²² may offer an opportunity to evaluate acute changes in myocardial perfusion in patients in intensive care units by means of pulmonary artery or central venous catheter injections.

The gold standard angiography enables assessment of coronary anatomy, but does not offer an accurate means for assessing regional myocardial blood flow.²³ Nevertheless, short of coronary arteriography, the surgeon, cardiologist, or anesthesiologist is unable to directly assess the success of coronary revascularization in providing flow to myocardial tissue. This inability may be especially troublesome when an unexpected event occurs to a patient who has recently undergone CABG surgery. The differential diagnosis includes an inadequate operation, graft occlusion, or some other unrecognized event not related to graft patency. Etiology can only be definitely determined by cardiac catheterization.

Contrast echocardiographic techniques performed in the catheterization laboratory in conjunction with coronary arteriography appear to provide valuable information on myocardial perfusion not available through tra-

ditional angiographic techniques;²⁴ however, use during cardiac surgery has been limited by technical and methodological problems. These problems include intracoronary injections of contrast agents through small-gauge needles that cause the microbubbles to break down under pressure; injecting contrast into the aortic root without cross-clamping the aorta so that an unsatisfactory concentration of contrast flows retrograde into the coronary sinus and, consequently, into the coronary arteries and myocardium; or injecting unstable, and hence undetectable, contrast agents into the left atrium and left ventricle. We have described a method using aortic root injections of contrast through a cardioplegia catheter during CPB with the proximal aorta occluded. This method reliably demonstrates regional perfusion defects associated with coronary artery occlusion. We believe, in time, with the introduction of new stable contrast agents, injections from both right- and left-sided circulations will be possible.²⁵ However, these agents currently do not exist or are not approved for commercial use. We attempted to provide a method of using the technology of contrast echocardiography at present in the operating room to assist the surgeon and anesthesiologist in evaluating the adequacy of myocardial perfusion after coronary revascularization.

This technique allows for the assessment of myocardial perfusion after coronary artery revascularization while cardiopulmonary bypass is still occurring. The images are obtained while the heart is arrested in diastole with the ascending aorta occluded. We have previously assessed myocardial perfusion without the aorta occluded *via* aortic root and left atrial injections of contrast in a beating heart; however, such assessment requires either a special contrast agent that is highly concentrated and stable—and not yet FDA approved—to image myocardial perfusion on-line, or an off-line analysis with a special computer to detect the enhanced myocardial perfusion with the injection of currently available contrast agents (*i.e.*, renograffin).

A potential benefit of contrast echocardiography may be the assessment of regional myocardial perfusion in those patients who are difficult to wean from cardiopul-

monary bypass. Such knowledge might be used to guide and evaluate decisions about therapies. For example, if poor perfusion of the anterior region of the heart occurred after a saphenous vein graft, a decision to redo the graft, to increase blood pressure with phenylephrine, or to relieve the spasm with nitroglycerin might be made. A subsequent contrast echogram could then assess the perfusion results of the chosen therapy.

Another potential benefit of myocardial contrast echocardiography would be to correlate functional wall motion changes with graded changes in myocardial perfusion immediately following coronary bypass surgery to assess myocardium at risk of infarction. This analysis was, however, beyond the scope of this study because analysis of myocardial perfusion was done while the heart was arrested in diastole before separating from cardiopulmonary bypass.

We believe the future of contrast echocardiography will allow the direct assessment of regional myocardial perfusion in the operating room and that further studies are needed to assess the perioperative clinical potential of this technology, as it continues to evolve.

References

1. Skorton DJ, Collins SM: New directions in cardiac imaging. *Ann Intern Med* 102:795-799, 1985
2. Marcus ML, White CW: Coronary flow reserve in patients with normal coronary angiograms. *J Am Coll Cardiol* 6:1245-1246, 1986
3. Serwer GA, Armstrong BE, Anderson PA, Sherman D, Benson DW, Edwards SB: Use of ventricular septal defects. *Circulation* 58:327-336, 1978
4. Melzer RS, Hoogenhuyze DV, Serruys PW: Diagnosis of tricuspid regurgitation by contrast echocardiography. *Circulation* 63:1093, 1981
5. Roelandt J: Contrast echocardiography. *Ultrasound Med Biol* 8:471-492, 1982
6. DeMaria A, Bommer W, Kuan OL, Riggs K, Smith M, Waters J: *In vivo* correlation of thermodilution cardiac output and video-densitometry indicator-dilution curves obtained from contrast two-dimensional echocardiograms. *J Am Coll Cardiol* 3:999-1004, 1984
7. Goldman, ME, Mindich, BP, Teichholz, LE, Burgess N, Staville K, Fuster V: Intraoperative contrast echocardiography to evaluate mitral valve operations. *J Am Coll Cardiol* 4:1035-1040, 1984
8. Kemper AJ: Myocardial contrast echocardiography. *In vivo* imaging of regional myocardial perfusion abnormalities. *Echocardiography* 1:495-505, 1984
9. Feinstein SB: Myocardial perfusion imaging: Contrast echocardiography today and tomorrow. *J Am Coll Cardiol* 8:251-253, 1986
10. Armstrong WF, West SR, Mueller TM, Dillon JC, Feigenbaum H: Assessment of location and size of myocardial infarction abnormalities with contrast-enhanced echocardiography. *J Am Coll Cardiol* 2:63-69, 1983
11. Armstrong WF, Mueller TM, Kinney EL: Assessment of myocardial perfusion abnormalities with contrast enhanced two-dimensional echocardiography. *Circulation* 66:166-173, 1982
12. Kemper AJ, Force T, Perkins L, Gilfoil M, Parisi AF: *In vivo* prediction of the transmural extent of experimental acute myocardial infarction using contrast echocardiography. *J Am Coll Cardiol* 8:143-149, 1986
13. Lang RM, Feinstein SB, Feldman T, Neumann A, Chua KG, Borow KM: Contrast echocardiography for evaluation of myocardial perfusion: Effects of coronary angioplasty. *J Am Coll Cardiol* 8:232-235, 1986
14. Feinstein SB, Ten Cate FJ, Zwehl W, Ong K, Maurer G, Tei C, Shah PM, Meerbaum S, Corady E: Two dimensional contrast echocardiography. *In vitro* development and quantitative analysis of echo contrast agents. *J Am Coll Cardiol* 3:6-13, 1984
15. Page DL, Caulfield JB, Kastor JA, De Santis LW, Sanders CA: Myocardial changes associated with cardiogenic shock. *N Engl J Med* 285:133-137, 1971
16. Weiss JL, Bulkley BH, Hutchins GM, Mason SJ: Two-dimensional echocardiographic recognition of myocardial injury in man: Comparison with post mortem studies. *Circulation* 63:401-408, 1981
17. Wyatt HL, Meerbaum S, Heng MK: Experimental evaluation of the extent of myocardial dyssynergy and infarct size by two-dimensional echocardiography. *Circulation* 63:607-614, 1981
18. Lieberman AN, Weiss JL, Juddutt BL, Becker LC, Bulkley BH, Garrison JG, Hutchins GM, Kellman CA, Weisfeldt ML: Two-dimensional echocardiography and infarct size relationship of regional wall motion and thickening to the extent of myocardial infarction in the dog. *Circulation* 63:739-746, 1981
19. Nieminen M, Parisi AF, O'Boyle JE, Folland ED, Khuri S, Kloner RA: Serial evaluation of myocardial thickening and thinning in acute experimental infarction: Identification and quantification using two-dimensional echocardiography. *Circulation* 66:174-180, 1982
20. Bommer WS, Shah PM, Allen H, Meltzer R, Kisslo J: The safety of contrast echocardiography. *J Am Coll Cardiol* 3:6-13, 1984
21. Gillam LD, Kaul S, Fallon JT, Levine RA, Hedley-Whyte GT, Guerrero JL, Weyman AE: Functional and pathologic effects of multiple echocardiographic contrast injections on the myocardium, brain, and kidney. *J Am Coll Cardiol* 63:687-694, 1985
22. Feinstein SB, Heidenreich PA, Dick CD, Schneider AF, Pastoret AF, Rubenstein WA, Apfelbaum J, Brehm JL, Aronson S, Ellis J, Roizen M: Albutex®: Assessment of myocardial perfusion by contrast echocardiography (abstract). *Circulation* 78 II:565, 1988
23. White CW, Wright CB, Doty DB, Hiratzka LF, Gasthan CL, Harrison DG, Marcus ML: Does visual interpretation of the coronary arteriogram predict the physiologic importance of a coronary stenosis. *N Engl J Med* 310:819-824, 1984
24. Feinstein SB, Lang RM, Dick CD, Newman A, Al-Sadir J, Chua KG, Carroll J, Feldman T, Borow KM: Contrast echocardiography during coronary angiography in humans: Perfusion and anatomical studies. *J Am Coll Cardiol* 11:59-65, 1988
25. Dick C, Heidenreich P, Aronson S, Glock D, Tamler B, Feinstein S: Reproducible myocardial perfusion with intravenous contrast echocardiography (abstract). *Circulation* 78 II:565, 1988